



Supplementary Material

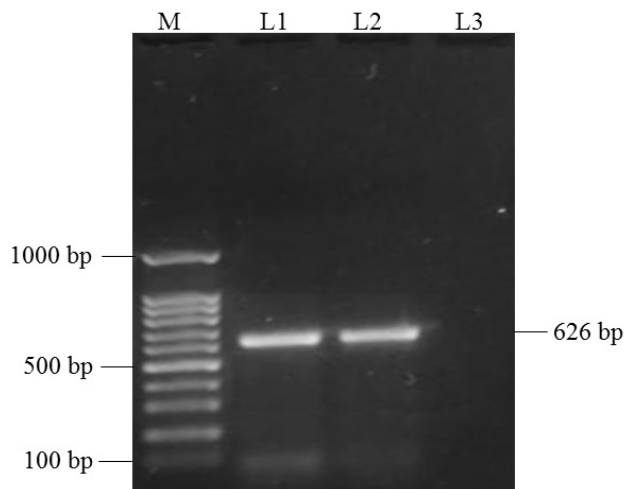
Molecular, Serological and Pathological Detection of *Mycobacterium avium* subsp. *paratuberculosis* Infection in Small Ruminants in Peshawar, Pakistan

Muhammad Izhar ul Haque¹, Farhan Anwar Khan^{1*}, Umar Sadique¹, Hamayun Khan¹, Zia ur Rehman¹, Salman Khan¹, Hayatullah Khan^{1,2}, Faisal Ahmad^{1,3}, Mumtazur Rahman¹, Faiz Ur Rehman¹, Muhammad Saeed¹, Mehboob Ali¹ and Saqib Nawaz¹

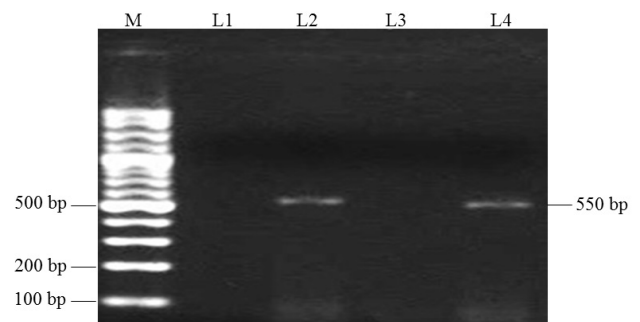
¹Department of Animal Health, Faculty of Animal Husbandry and Veterinary Sciences, The University of Agriculture, Peshawar, Pakistan

²Directorate of Livestock and Dairy Development (Extension), Peshawar, 25000, Khyber Pakhtunkhwa, Pakistan

³Directorate of Livestock and Dairy Development (Research), Peshawar, 25000, Khyber Pakhtunkhwa, Pakistan



Supplementary Fig. 1. Polymerase chain reaction targeted specific IS900 region of MAP.



Supplementary Fig. 2. Polymerase chain reaction targeted specific IS1311 region of MAP.

* Corresponding author: farhan82@aup.edu.pk
0030-9923/2023/0001-307 \$ 9.00/0



Copyright 2022 by the authors. Licensee Zoological Society of Pakistan.

This article is an open access  article distributed under the terms and conditions of the Creative Commons Attribution (CC BY) license (<https://creativecommons.org/licenses/by/4.0/>).